

The Essentials: Conundrums in anticoagulation & paroxysmal atrial fibrillation

“I do NOT want a stroke!”

1. POAF is usually transient and intermittent resolving in approximately 6 weeks

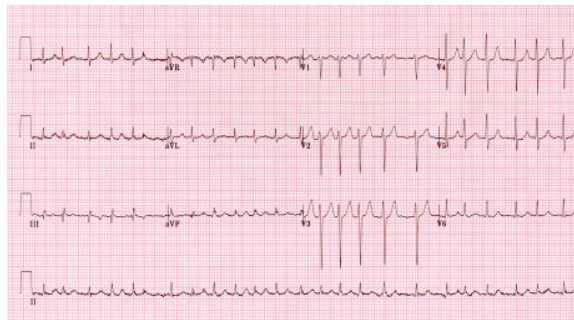


2. Long term OAC is not indicated in isolated POAF

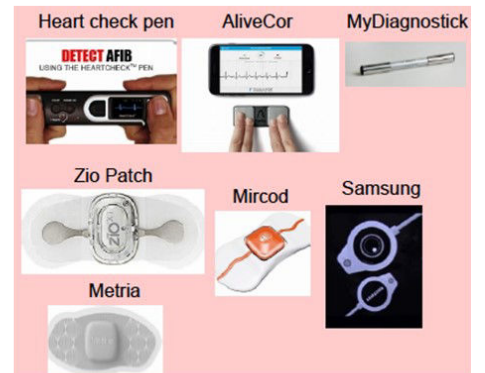

4. Not all screened detected AF warrants OAC

- Individualize treatment
- Document with 12-lead ECG



3. Wearable technology, accessible to the general public, can document AF with high sensitivity



5. In device detected AF, continuous episodes lasting >24hrs, it is reasonable to prescribe OAC

- OAC reasonable in patients ≥ 65 years or CHADS2 score ≥ 1 with subclinical AF > 24 hour

