

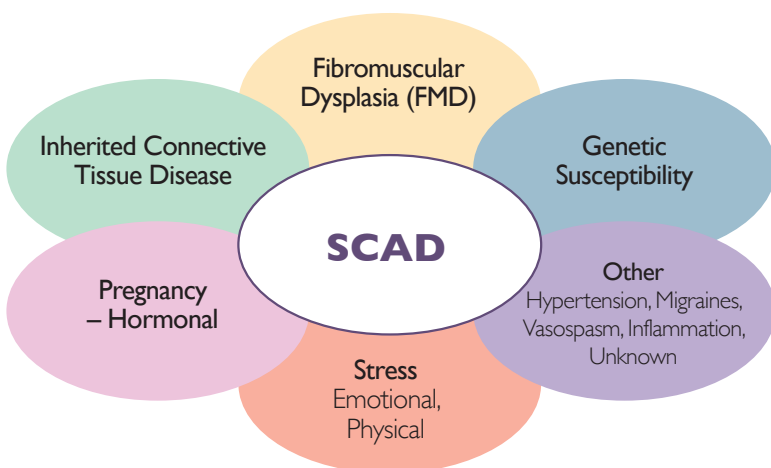
The Essentials: Spontaneous Coronary Artery Dissection (SCAD)

“Doctor, what happened to me?”

Diagnosis



Most common in women (~90%).
Requires angiography.
Precipitating and/or associated factors often present.



Treatment

1. Treat conservatively when possible:

- unless hemodynamic instability or high-risk coronary anatomy

Antiplatelets (controversial, divergent practice)

- if PCI, as per Guidelines
- if not, ASA only vs. brief DAPT

ACE-I, ARB, MRA

- if EF low

Betablockers

- if HTN
- may reduce recurrence

Calcium channel blockers, nitrates

- if recurrent chest pain

Statins

- only if hyperlipidemia

Avoid

- systemic hormones
- thrombolytics

2. Observe in-hospital for early, clinically significant progression.

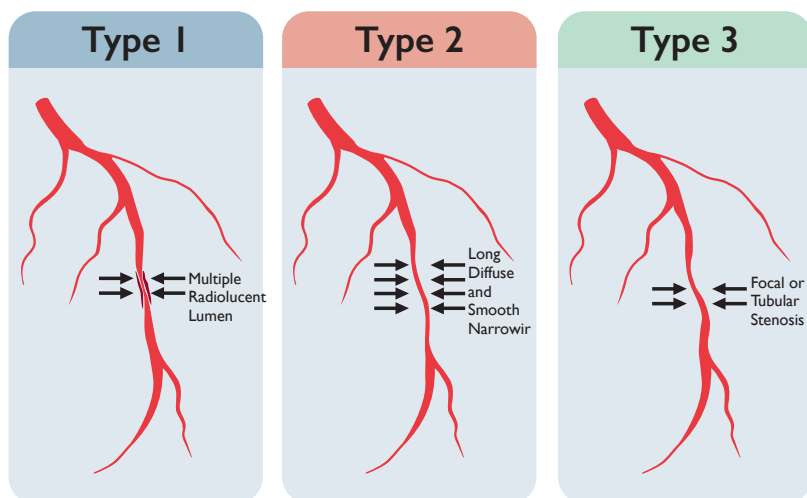
- elevated troponin, dynamic ECG changes
- repeat angiography, and intervention (PCI or CABG) if indicated

3. Chest pain after SCAD for several months is common and doesn't necessarily indicate recurrence

- consider noninvasive imaging (CTA) or stress testing
- if severe, with troponin elevation: repeat angiography

4. Intervene when indicated.

Angiographic Classification



Life after SCAD

Refer for cardiovascular rehab – safe and beneficial.

- avoid heavy lifting (>30lbs) or extreme endurance events

Mental health supports for anxiety, depression, PTSD.

Reproductive concerns:

- Menorrhagia (minimize DAPT)
- Avoid exogenous hormones
- Contraception: IUD or sterilization
- Discourage pregnancy
- Multidisciplinary approach if it occurs

Dedicated, long-term, out-patient cardiology follow-up recommended.

SCAD Registry enrollment if available

- Dr. Saw registry:
<https://scad.ubc.ca/canadian-scad-study/>

